

Surgical Anatomic Evaluation of the Cervical Pedicle and Adjacent Neural Structures

Hasan Çağlar Uğur, M.D., Ayhan Attar, M.D.,
Aysun Uz, M.D., İbrahim Tekdemir, M.D.,
Nihat Egemen, M.D., Sukru Çağlar, M.D.,
Yasemin Genç, M.A.

Departments of Neurosurgery (HÇU, AA, NE, SÇ), Anatomy (AU, İT), and
Biostatistics (YG), University of Ankara, Ankara, Turkey

OBJECTIVE: Although several clinical applications of transpedicular screw fixation in the cervical spine have been documented recently, few anatomic studies concerning the cervical pedicle are available. This study was designed to evaluate the anatomy and adjacent neural relationships of the middle and lower cervical pedicle (C3–C7). The main objective is to provide accurate information for transpedicular screw fixation in the cervical region and to minimize complications by providing a three-dimensional orientation.

METHODS: Twenty cadavers were used to observe the cervical pedicle and its relationships. After removal of the posterior bony elements, including spinous processes, laminae, lateral masses, and inferior and superior facets, the isthmus of the pedicle was exposed. Pedicle width, pedicle height, interpedicular distance, pedicle-inferior nerve root distance, pedicle-superior nerve root distance, pedicle-dural sac distance, medial pedicle-dural sac distance, mean angle of the pedicle, root exit angle, and nerve root diameter were measured.

RESULTS: The results indicate that there was no distance between the pedicle and the superior nerve root and between the pedicle and the dural sac in 16 specimens, whereas there was a slight distance in the lower cervical region in the 4 other specimens. The mean distance between the pedicle and the inferior nerve root for all specimens ranged from 1.0 to 2.5 mm. The mean distance between the medial pedicle and the dural sac increased consistently from 2.4 to 3.1 mm. At C3–C7, the mean pedicle height ranged from 5.2 to 8.5 mm, and the mean pedicle width ranged from 3.7 to 6.5 mm. Interpedicular distance ranged from 21.2 to 23.2 mm. The mean root exit angle ranged from 69 to 104 degrees, with the largest angle at C3 and the smallest at C6. The mean angle of the pedicle ranged from 38 to 48 degrees. The nerve root diameter increased consistently from 2.7 mm at C3 to 3.8 mm at C6 and then decreased to 3.7 mm at the C7 level. Differences in measurements were considered statistically significant at levels ranging from $P < 0.05$ to $P < 0.01$.

CONCLUSION: This study indicates that improper placement of the pedicle screw medially and superiorly in the middle and lower cervical spine should be avoided and that the anatomic variations between individuals should be established by measurement. (Neurosurgery 47:1162–1169, 2000)

Key words: Anatomy, Cadaver, Cervical pedicle, Transpedicular fixation

Surgical stabilization of the unstable cervical spine can be achieved by spinous process wiring, triple wire technique, sublaminar wiring, posterolateral mass plating, and anterior vertebral body plating (1, 2). The technique used basically depends on the main pathological findings and the extent of the surgeon's experience. All plating techniques are proven to provide superior fixation when absent or deficient spinous processes prevent the use of most wiring techniques. They are also known for their superiority for fixation in cases

of multilevel instability. The lateral mass has been a site of choice for screw placement in posterior cervical plating. When the proximity of lateral mass screws to the vertebral arteries, cervical nerve roots, and the spinal cord and the possibility of screw loosening or avulsion are taken into consideration, this technique may pose risks. However, few incidents of this nature are reported in the literature. On the other hand, posterior plating by the use of transpedicular screw fixation has been reported to be in use at a few centers as a treatment

of choice. Transpedicular screw fixation can be used for the treatment of instability of the cervical spine caused by trauma, tumor, infection, degenerative conditions, and failed anterior fusion (1).

Compared with the lateral mass screwing technique, the transpedicular screwing technique, because of the close anatomic relationships, may involve greater and more serious risks. Quantitative anatomic studies of the thoracic and lumbar vertebral pedicle have been reported more frequently than studies of the cervical pedicle. Nevertheless, because of the unique anatomic structures of the cervical pedicle and adjacent neural structures (10), more accurate quantitative anatomic data are needed to avoid or minimize neural complications. The main purpose of the current study is to highlight the pedicle anatomy and to provide three-dimensional orientation while emphasizing the risks involved in performing the technique (4), owing to its unique localization and its important neural relationships.

MATERIALS AND METHODS

Twenty cadavers (14 men and 6 women; age, 24–72 yr) obtained from the Department of Anatomy were used for the current study of the cervical pedicle and adjacent relationships. Specimens having gross deformities, such as scoliosis or kyphosis, were excluded from the study. The cadavers were placed in the prone position with the neck in a neutral position. Each specimen was prepared by complete removal of all soft tissue from the vertebra (Fig. 1). A laminar rongeur and a Kerrison rongeur were used to remove the spinous processes, laminae, lateral masses, and superior and inferior

facets and expose the cervical pedicle. Microdissections were then performed until the isthmus (the most narrow pedicle diameter) was exposed (Fig. 2).

All dissections and measurements were performed by two experienced neurosurgeons and two experienced anatomists. They unanimously decided on each appropriate measurement site for every parameter and concurred on the accuracy of the measurements. All measurements were precisely hand-calibrated (0.1 mm), thus enabling the identification of easily recognizable points of structures on each vertebra. Standard goniometers (precision, 1 degree) were used in performing angular measurements. The following measurements were obtained (Fig. 3): 1) pedicle width at isthmus; 2) pedicle height at isthmus; 3) interpedicular distance; 4) pedicle-inferior nerve root distance (distance from the inferior border of the pedicle to the superior limit of the adjacent nerve root); 5) pedicle-superior nerve root distance (PSRD) (distance from the superior border of the pedicle to the inferior limit of the adjacent nerve root); 6) pedicle-dural sac distance (PDSD) (distance between the superior border of the pedicle and the lateral limit of the dural sac); 7) medial PSDS (distance between the medial pedicle and the dural sac); 8) mean angle of the pedicle (with respect to the vertebral midline in the transverse plane); 9) root exit angle (angle between the midline and the axis of the nerve root in the frontal plane); and 10) nerve root diameter (superior-inferior diameter of the nerve root at the midpoint of the pedicle).

Analyses of all measurements (mean values, standard deviations, and ranges) were performed and calculated for each parameter. Parameters for male and female subjects were




FIGURE 1. Photograph of the cervical region after removal of all soft tissue from vertebrae. *s*, spinous process; *l*, lamina; arrows, facet joint.

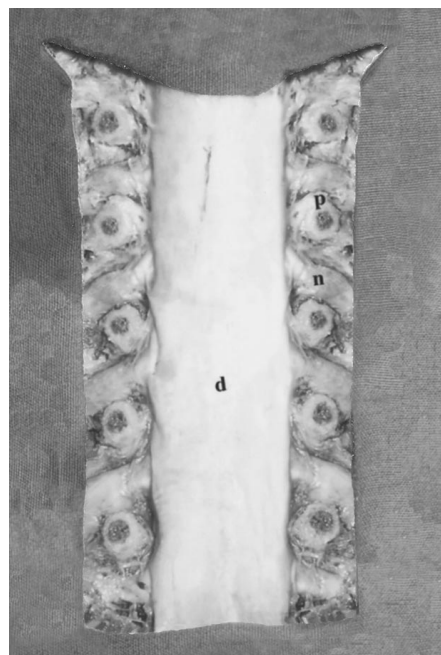


FIGURE 2. Photograph showing pedicle (*p*), nerve root (*n*), and dural sac (*d*).

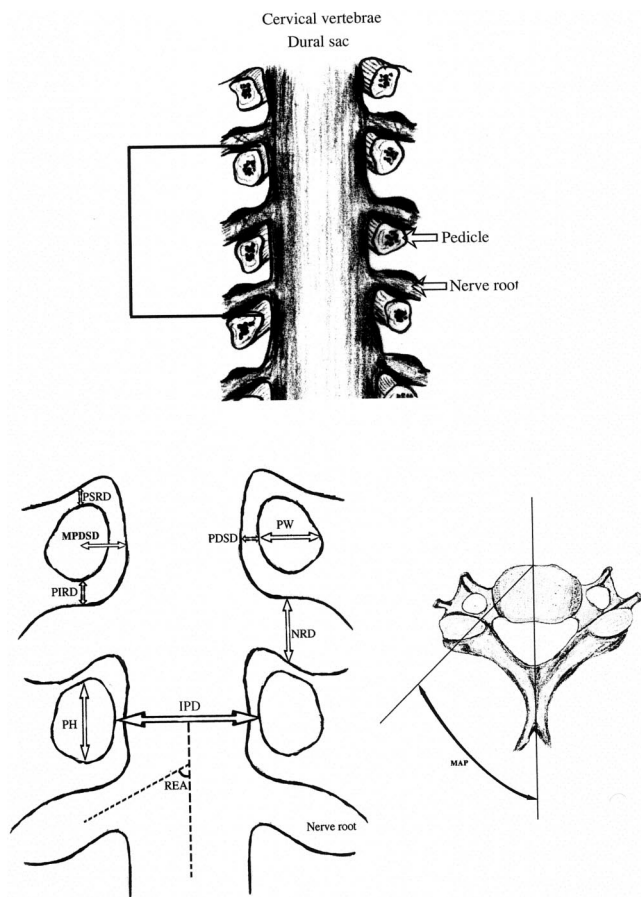


FIGURE 3. Drawing showing the pedicles and nerve roots (A) and diagrams indicating the measurements (B). *PW*, pedicle width; *PH*, pedicle height; *IPD*, interpedicular distance; *PIRD*, pedicle-inferior nerve root distance; *PSRD*, pedicle-superior nerve root distance; *PDS*, pedicle-dural sac distance; *MPDSD*, medial pedicle-dural sac distance; *REA*, root exit angle; *NRD*, nerve root diameter; *MAP*, mean angle of the pedicle.

compared by using the Mann-Whitney *U* test, and differences between measurements for males and females were considered significant at levels ranging from $P < 0.05$ to $P < 0.01$.

RESULTS

The results of the current study, based on the dissection of 20 cadaver spines, quantitatively describe the anatomic relationships of the cervical pedicles to each other and to the adjacent neural structures (Tables 1-3; Fig. 4).

Pedicle width, pedicle height, and interpedicular distance

The results of analysis of the pedicle dimensions are shown in Table 1 and Figure 4. The pedicle width and height were greater in males than in females for most of the levels measured. Interpedicular distance was greatest at the C7 level;

there was no significant difference between males and females ($P > 0.05$).

Pedicle-inferior nerve root distance and medial PDS

The mean pedicle-inferior nerve root distance for the C3–C7 levels in all specimens ranged from 1.0 to 2.5 mm, with the largest value seen at C7. The mean distance between the medial pedicle and the dura increased consistently from 2.4 to 3.1 mm.

PSRD and PDS

In 16 cadavers, no distance was found between the superior border of the pedicle and the inferior limit of the adjacent nerve root and between the medial border of the pedicle and the lateral border of the dural sac at the C3–C7 levels, whereas there was a slight distance in the lower cervical region in the other 4 cadavers.

Mean angle of pedicles

The mean angle of the pedicles ranged from 38 to 48 degrees. The smallest angle was measured at C3, and the largest was found at C5.

Root exit angle

The mean nerve root angle in the frontal plane ranged between 74 and 104 degrees. The smallest angle was observed at C6, and the largest was found at C3. There were significant differences between males and females in the middle cervical region ($P < 0.05$).

Nerve root diameter

The smallest superior-inferior diameter of the nerve root was found at C3, and the largest was at C6. There were significant differences between males and females at the C4 to C7 levels ($P < 0.05$).

DISCUSSION

Posterior pedicle screw fixation in the cervical region has become the treatment of choice in some centers; therefore, accurate anatomic knowledge and orientation are needed because of the unique structures of the cervical pedicle and its important neural relationships. On the basis of biomechanical studies of cervical fixation procedures, the posterior transpedicular screw technique has been found to be superior to the other techniques (6, 8); however, because of the risks to adjacent neural structures, the application of the technique requires great caution to ensure safety. Pedicle screw fixation systems have been widely used for reconstruction of the thoracic and lumbar spine. However, there are fewer reported cases in which this technique was used in the cervical region.

The lack of anatomic and anatomoradiological studies (3, 5, 9, 11) delineating the cervical pedicle anatomy could account for the apprehensive attitude of many clinics toward application of the technique in the cervical region. Even those surgeons who make wide use of the technique in the thoracic and lumbar regions report few applications in the cervical area.

TABLE 1. Anatomic Parameters of the Cervical Pedicles Measured in 20 Cadavers^a

Cervical Level and Sex	PW (mm)		PH (mm)		IPD (mm)	
	Mean \pm SD	Range	Mean \pm SD	Range	Mean \pm SD	Range
C3						
All	4.9 \pm 0.5	3.7–5.4	6.3 \pm 0.5	5.2–7.0	21.8 \pm 1.1	19.4–23.1
Male	5.1 \pm 0.3	4.2–5.3	6.5 \pm 0.4 ^b	5.7–7.0	21.6 \pm 1.1	19.4–23.1
Female	4.5 \pm 0.8	3.7–5.4	5.7 \pm 0.5	5.2–6.4	22.4 \pm 0.7	21.9–22.9
C4						
All	5.2 \pm 0.6	3.9–5.9	6.5 \pm 0.5	5.2–7.1	21.1 \pm 1.3	19.0–23.6
Male	5.4 \pm 0.3 ^b	4.8–5.9	6.6 \pm 0.4 ^b	5.9–7.1	20.8 \pm 1.0	19.0–22.6
Female	4.5 \pm 0.8	3.9–5.6	5.9 \pm 0.5	5.2–6.5	22.5 \pm 1.6	21.4–23.6
C5						
All	5.3 \pm 0.6	3.7–5.8	6.4 \pm 0.7	5.3–7.2	21.2 \pm 1.8	18.4–23.4
Male	5.5 \pm 0.2 ^b	5.1–5.8	6.7 \pm 0.7 ^b	5.3–7.2	20.7 \pm 1.6	18.4–23.4
Female	4.4 \pm 0.9	3.7–5.6	5.6 \pm 0.2	5.4–5.7	23.2 \pm 0.0	23.2–23.2
C6						
All	5.7 \pm 0.4	4.9–6.4	6.6 \pm 0.6	5.4–7.4	22.3 \pm 2.3	19.2–25.1
Male	5.8 \pm 0.3 ^b	5.3–6.4	6.8 \pm 0.5 ^c	5.9–7.4	21.6 \pm 2.0	19.2–25.1
Female	5.3 \pm 0.4	4.9–5.6	5.9 \pm 0.6	5.4–6.7	25.1 \pm 0.1	25.0–25.1
C7						
All	6.0 \pm 0.3	5.1–6.5	6.9 \pm 0.7	5.7–8.5	23.2 \pm 2.2	20.0–26.7
Male	6.1 \pm 0.2	5.8–6.5	7.2 \pm 0.6 ^c	6.4–8.5	22.9 \pm 2.4	20.0–26.7
Female	5.7 \pm 0.5	5.1–6.1	6.1 \pm 0.4	5.7–6.5	24.5 \pm 1.1	23.7–25.2

^a PW, pedicle width; PH, pedicle height; IPD, interpedicular distance; SD, standard deviation.

^b $P < 0.05$.

^c $P < 0.01$.

This could be based on a lack of surgical experience owing to the inadequacy of information providing a clear understanding of the pedicle anatomy and the risks involved. Although the use of cervical pedicle screws may be indicated for patients with small or eroded lateral masses, as may occur with severe spondylosis or severe osteoporosis or when lateral screw fixation has failed, these indications remain limited. This technique can be considered an alternative method that can be used for stabilizing the cervical spine, rather than a technique that supplants lateral mass fixation.

Abumi and Kaneda (1) reported that 11 of 183 pedicle screws placed in the cervical spine penetrated the pedicle cortex. Fortunately, only one screw penetrating to the pedicle caused neurological symptoms. Very detailed data on the three-dimensional anatomy of the cervical vertebra were first reported by Panjabi et al. (9). They measured the dimensions of the vertebral body, spinal canal, and pedicle. Jeanneret et al. (5) presented an anatomic study of the cervical spine, and they recommended that the entrance point for transpedicular screw insertion be in the middle of the articular mass and 3 mm beneath the superior facet. A medial angle of 45 degrees in the transverse plane of C3–C7 was also proposed. Their results revealed that transpedicular screw fixation may be performed safely in the lower cervical spine.

Abumi and Kaneda (2) suggested that the point of screw penetration at the posterior cortex of the articular mass be determined slightly lateral to the center of the articular mass and close to the posterior margin of the superior articular surface, taking into consideration the location of the vertebral

artery, the spinal cord, and the pedicle. On the basis of our study's results, we propose a 40- to 45-degree pedicle entrance in the transverse plane. The results of the biomechanical study by Katoni et al. (8) showed that transpedicular screw fixation offers more stability than conventional plate or wiring techniques do. A large number of cases involving clinical application of transpedicular fixation for the treatment of unstable cervical spine caused by trauma, tumor, infection, degenerative conditions, and failed anterior fusion have been reported by Abumi and Kaneda (1). No complications were reported to involve injuries to the vertebral artery, spinal cord, or nerve root after surgery.

The mean diameters of the pedicles for the C3–C7 level measured in the current study ranged from 6.3 to 6.9 mm in height and 4.9 to 6.0 mm in width. There were significant differences between male and female specimens at most levels. These diameters are greater than those reported in the studies by Ebrahim et al. (3) and Xu et al. (11), and are similar to those reported by Panjabi et al. (9) and Karaikovic et al. (7). Placing pedicle screws at the C3 and C4 levels requires more care and smaller screws, because the diameters of these pedicles are smaller than those of other cervical vertebrae. There was a little distance between the pedicle and the inferior nerve root; it ranged from 1.5 to 1.7 mm, with the largest value at the C7 level. There was no distance for PSRD and PDS in 16 cadavers; in 4 other cadavers, there was a slight distance in the lower cervical region for PSRD and PDS. The measurement for PSRD was similar to the results of Xu et al. (11), whereas the measurement for PDS showed little differ-

TABLE 2. Anatomic Parameters of Distances from the Cervical Pedicles to the Adjacent Nerve Roots and Dural Sac Measured in 20 Cadavers^a

Cervical Level and Sex	PIRD (mm)		PSRD (mm)		PDS (mm)		MPDS (mm)	
	Mean ± SD	Range	Mean ± SD	Range	Mean ± SD	Range	Mean ± SD	Range
C3								
All	1.5 ± 0.3	1.0–1.9	0 ± 0	0–0	0 ± 0	0–0	2.4 ± 0.2	2.2–2.6
Male	1.5 ± 0.3	1.0–1.9	0 ± 0	0–0	0 ± 0	0–0	2.5 ± 0.3	2.2–2.9
Female	1.7 ± 0.3	1.4–1.9	0 ± 0	0–0	0 ± 0	0–0	2.2 ± 0.7	2.0–2.7
C4								
All	1.5 ± 0.2	1.2–2.0	0 ± 0	0–0	0 ± 0	0–0	2.6 ± 0.3	2.1–2.8
Male	1.4 ± 0.2 ^b	1.2–1.8	0 ± 0	0–0	0 ± 0	0–0	2.7 ± 0.1 ^b	2.3–3.0
Female	1.8 ± 0.3	1.5–2.0	0 ± 0	0–0	0 ± 0	0–0	2.2 ± 0.4	1.9–2.6
C5								
All	1.6 ± 0.2	1.2–2.1	0 ± 0	0–0	0 ± 0	0–0	2.7 ± 0.3	2.1–3.0
Male	1.5 ± 0.2	1.2–1.7	0 ± 0	0–0	0 ± 0	0–0	2.8 ± 0.1	2.5–2.9
Female	1.8 ± 0.4	1.3–2.1	0 ± 0	0–0	0 ± 0	0–0	2.2 ± 0.3	2.0–2.5
C6								
All	1.6 ± 0.3	1.0–2.4	0.1 ± 0.1	0–0.5	0.1 ± 0.1	0–0.4	2.9 ± 0.2	2.4–3.2
Male	1.5 ± 0.2 ^b	1.0–1.9	0.1 ± 0.2	0–0.5	0.1 ± 0.1	0–0.4	2.9 ± 0.1 ^b	2.4–3.2
Female	2.1 ± 0.4	1.6–2.4	0 ± 0	0–0	0 ± 0	0–0	2.7 ± 0.2	2.2–3.0
C7								
All	1.7 ± 0.4	1.0–2.5	0.2 ± 0.3	0–0.7	0.2 ± 0.3	0–1.0	3.1 ± 0.2	2.4–3.3
Male	1.6 ± 0.3	1.0–2.0	0.1 ± 0.2	0–0.7	0.1 ± 0.2	0–0.5	3.1 ± 0.2	2.3–3.2
Female	2.1 ± 0.6	1.5–2.5	0.3 ± 0.3	0–0.6	0.5 ± 0.5	0–1.0	2.9 ± 0.3	2.4–3.0

^a PIRD, pedicle-inferior root distance; PSRD, pedicle-superior root distance; PDS, pedicle-dural sac distance; MPDS, medial pedicle-dural sac distance; SD, standard deviation.

^b $P < 0.05$.

TABLE 3. Anatomic Parameters of Distances from the Cervical Pedicles to the Adjacent Nerve Roots and Angles Measured in 20 Cadavers^a

Cervical Level and Sex	REA (degrees)		NRD (mm)		MAP (degrees)	
	Mean ± SD	Range	Mean ± SD	Range	Mean ± SD	Range
C3						
All	86.7 ± 8.8	78–104	2.7 ± 0.2	2.3–3.1	38 ± 4.2	27–49
Male	84.3 ± 7.3 ^b	78–99	2.7 ± 0.2	2.3–3.1	39 ± 5.2	30–49
Female	96.3 ± 8.4	89–104	2.5 ± 0.2	2.3–2.7	38 ± 4.5	27–40
C4						
All	84.9 ± 7.9	74–98	3.2 ± 0.5	2.6–4.2	47 ± 6.1	41–53
Male	82.6 ± 6.9 ^b	74–97	3.3 ± 0.4 ^b	2.8–4.2	49 ± 5.9	41–53
Female	94.3 ± 3.3	91–98	2.8 ± 0.2	2.6–3.0	45 ± 4.4	42–47
C5						
All	81.8 ± 5.4	71–92	3.6 ± 0.5	3.0–5.1	48 ± 4.2	38–56
Male	80.2 ± 4.2 ^b	71–88	3.7 ± 0.5 ^b	3.0–5.1	51 ± 5.2 ^b	41–56
Female	88.3 ± 5.2	81–92	3.1 ± 0.1	3.0–3.2	46 ± 5.0	38–52
C6						
All	80.9 ± 8.0	70–91	3.8 ± 0.3	3.2–4.3	43 ± 8.1	29–50
Male	81.0 ± 7.4	71–90	3.9 ± 0.2 ^c	3.4–4.3	45 ± 4.5	40–50
Female	80.5 ± 11.6	70–91	3.5 ± 0.2	3.2–3.6	41 ± 6.2	29–47
C7						
All	85.5 ± 8.7	69–95	3.7 ± 0.4	2.8–4.4	45 ± 3.9	38–57
Male	84.9 ± 9.1	69–94	3.8 ± 0.3 ^b	3.4–4.4	46 ± 6.1	40–57
Female	88.0 ± 7.5	81–95	3.3 ± 0.4	2.8–3.6	41 ± 3.2 ^c	38–50

^a REA, root exit angle; NRD, nerve root diameter; MAP, mean angle of the pedicle; SD, standard deviation.

^b $P < 0.05$.

^c $P < 0.01$.

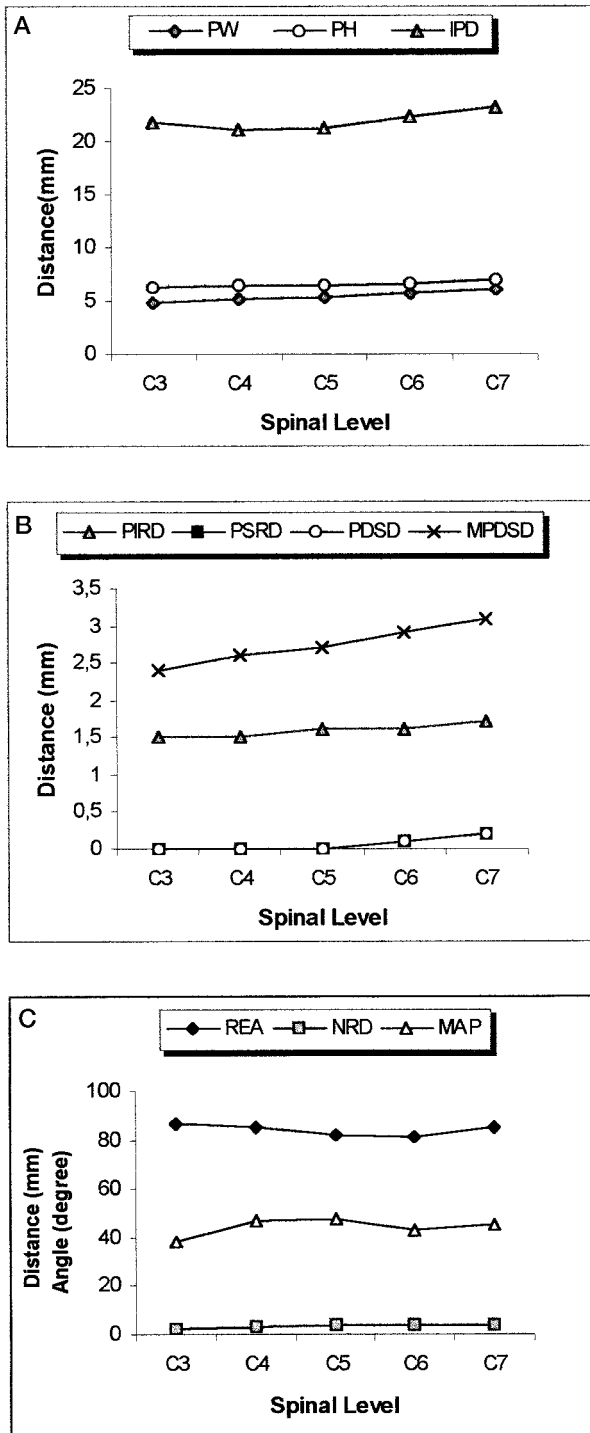


FIGURE 4. Vertebral levels and measurements of cervical pedicle and adjacent neural structures measured in 20 cadavers. *A*, PW, pedicle width; PH, pedicle height; IPD, interpedicular distance. *B*, PIRD, pedicle-inferior nerve root distance; PSRD, pedicle-superior nerve root distance; PDSD, pedicle-dural sac distance; MPDSD, medial pedicle-dural sac distance. *C*, REA, root exit angle; NRD, nerve root diameter; MAP, mean angle of the pedicle.

ence in the current study. This shows that the incidence of neurological injuries may be higher in screw penetration of the medial and superior cortex of the pedicle, especially in the middle cervical region. When the distance between the pedicle and inferior nerve root (1.5–1.7 mm) is considered, inferior pedicle cortex penetration also runs a very high risk of neurological deficit.

The structures of the pedicle in the middle and lower cervical region can vary among individuals, so preoperative axial tomography and conventional radiography may help to enhance the safety of transpedicular screw fixation before surgery in this region and may indicate the size of the screws to be used. Because of its correlation with significant morbidity, the pedicle screw fixation technique also requires a thorough knowledge of pedicle anatomy, a well-planned preoperative preparation, and great care during surgery.

Although successful and encouraging results are presented in some studies, the very serious nature of the possible complications that may emerge during surgery, such as lack of fixation and nerve root or spinal cord injury, should not be disregarded. Reported studies are sparse in this area, and the true incidence of complications is not certain. Because of the possibility of underreporting of such occurrences, the rate of complications might be much higher than estimated. Our results show that cervical pedicles have a unique structure, and they have very important relationships with neural structures. More anatomic/anatomoradiological studies on the cervical pedicle, with three-dimensional orientation, are needed to ensure successful surgery and minimize complications.

Received, January 27, 2000.

Accepted, June 16, 2000.

Reprint requests: Hasan Çağlar Uğur, M.D., Ankara Üniversitesi Tıp Fakültesi, İbn-i Sina Hastanesi, Norosirurji Bölümü, Sıhhiye/Ankara, Turkey. Email: hasanugur2000@hotmail.com

REFERENCES

1. Abumi K, Kaneda K: Transpedicular screw fixation for reconstruction of the cervical spine. Presented at the 62nd Meeting of the American Academy of Orthopedic Surgeons, Orlando, Florida, February 18, 1995.
2. Abumi K, Kaneda K: Pedicle screw fixation for nontraumatic lesions of the cervical spine. *Spine* 22:1853–1863, 1997.
3. Ebrahim NA, Xu R, Knight T, Yeasting RA: Morphometric evaluation of lower cervical pedicle and its projection. *Spine* 22:1–6, 1997.
4. Esses SI, Sachs BL, Dreyzin V: Complications associated with the technique of pedicle screw fixation: A selected survey of ABS members. *Spine* 18:2231–2239, 1993.
5. Jeanneret B, Gebhard JS, Magerl F: Transpedicular screw fixation of articular mass fracture-separation: Results of an anatomical study and operative technique. *J Spinal Disord* 7:222–229, 1994.
6. Jones EL, Heller JG, Silcox DH, Hutton WC: Cervical pedicle screws versus lateral mass screws. *Spine* 22:977–982, 1997.
7. Karaikovic EE, Daubs MD, Madsen RW, Gaines RW: Morphologic characteristic of human cervical pedicles. *Spine* 22:493–500, 1997.
8. Katoni Y, Cunningham BW, Abumi K, McAffy PC: Biomechanical analysis of cervical stabilization systems. *Spine* 19:2529–2539, 1994.

9. Panjabi M, Duranceau J, Goel V, Oxland T, Takata K: Cervical human vertebra: Quantitative three-dimensional anatomy of the middle and lower regions. *Spine* 16:861-869, 1991.
10. Pech P, Daniels DL, Williams AL, Haughton VM: The cervical neural foramina: Correlation of microtomy and CT anatomy. *Radiology* 155:143-146, 1985.
11. Xu R, Kang A, Ebrahim NA, Yeasting RA: Anatomic relation between cervical pedicle and the adjacent neural structures. *Spine* 24:451-454, 1999.

COMMENTS

Uğur et al. have provided, in a meticulous manner, relevant anatomy pertaining to cervical pedicle screw fixation. The authors observed that there is a tight relationship between the medial and rostral portion of the pedicle, dural, and neural structures. On the basis of this information, placement of the pedicle screw in the mid to low cervical spine caudally and slightly laterally in the pedicle is encouraged. It is of note that the upper cervical (C3 and C4) pedicles are small; therefore, pedicle fixation may be unwise in this region. Anatomic data of this type are critical and provide much needed information to those of us who choose to embark on the endeavor of cervical pedicle fixation. Cervical pedicle fixation indeed provides a structurally sound construct. Its risks, however, must be carefully considered. For it to be used effectively and safely, a clear understanding of the anatomy, such as that provided by Uğur et al., is imperative.

Edward C. Benzel
Cleveland, Ohio

Although pedicle screw fixation is the method of choice for instrumentation of the unstable lumbar spine and is used increasingly for the stabilization of the thoracic spine, the unique anatomy of the cervical spine has made pedicle screw fixation in this region quite problematic and, for the most part, unnecessary. Extensive experience with the use of lateral mass screws and plates over the past 20 years has demonstrated that this technique is safe and efficacious. Screw pull-out is infrequent, and even when it does occur, fixation is infrequently lost. In addition, the anatomic relationships of the lateral mass to the spinal cord, nerve roots, and vertebral artery are such that injury to neural or vascular structures is extremely uncommon. Screw placement in the lateral mass is easily learned and may be safely and effectively performed by the novice who pays attention to the anatomy.

On the other hand, stabilization of the cervical spine using pedicle screw fixation is technically demanding and is fraught with pitfalls for the inexperienced or unwary neurosurgeon. The pedicles are small compared with those in the lumbar or thoracic spine and are only 2 mm wider than screws one might consider using; the nerve roots and dural tube are so close to the pedicle that even small medial misplacement of a screw may injure neural structures. Lateral screw deviation could easily penetrate the foramen transversarium, injuring the vertebral artery, which is an eventuality that the authors do not discuss.

The indications for the use of cervical pedicle screws would seem quite limited, perhaps in those few situations in which

the lateral masses are eroded or otherwise unsuitable for screw placement. Although excellent results using cervical pedicle screws have been reported by Abumi and Kaneda (1, 2), the technical challenges of screw placement preclude the widespread use of this procedure by the surgeon who performs only an occasional operation. However, in the future, it is possible that the safety and accuracy of screw placement will be enhanced by stereotactic guidance.

Paul R. Cooper
New York, New York

1. Abumi K, Kaneda K: Transpedicular screw fixation for reconstruction of the cervical spine. Presented at the 62nd Meeting of the American Academy of Orthopedic Surgeons, Orlando, Florida, February 18, 1995.
2. Abumi K, Kaneda K: Pedicle screw fixation for nontraumatic lesions of the cervical spine. *Spine* 22:1853-1863, 1997.

This article by Uğur et al. is a timely analysis of the cervical pedicle. Placement of cervical pedicle screws is gaining moderate acceptance in Europe and in Japan and is being considered increasingly in the United States. Fluoroscopically based guidance systems for surgical navigation may make placement of pedicle screws technically safer, which will encourage their use. Therefore, an analysis of the shape and dimensions of the cervical pedicles is an important step toward understanding the techniques that might enable the safe placement of cervical pedicle screws. The observation that there is slightly more room between the pedicle and the inferior nerve root and dura than between the pedicle and the superior nerve root and dura is significant, not only for the safe placement of pedicle screws, but for the posterior approaches to lateral disk herniation as well.

One question that may be asked is: given the high success rate of lateral mass plating, why would one want to place pedicle screws instead of lateral mass screws? Biomechanical studies have shown that pedicle screws have significantly greater rigidity than lateral mass screw plate systems. It is possible that some instances of posterior cervical stabilization may require more rigidity than that provided by lateral mass plating, or, in some instances, a concurrent anterior procedure might be avoided if increased cervical rigidity can be achieved with pedicle screws. Thus, placement of cervical pedicle screws may become part of our surgical armamentarium for a limited number of cases. However, in that lateral mass plating can be performed much more rapidly than cervical pedicle screw placement, it seems unlikely that placement of cervical pedicle screws will entirely replace our current techniques of lateral mass plating.

Richard G. Fessler
Chicago, Illinois

Uğur et al. have performed a cadaveric anatomic study of the cervical spine with specific reference to the cervical pedicles and the adjacent neural structures. This report and the information the authors provide are useful to neurosur-

geons who perform craniocervical or cervicothoracic reconstruction procedures. Internal fixation via the cervical pedicle does provide rigid internal fixation of the cervical spine. It is not meant to be a replacement for the more common application of lateral mass plates and screws, but it is an option for spinal surgeons in circumstances in which more rigid fixation is necessary or, for whatever reason, lateral mass screws are contraindicated. We use cervical pedicle fixation, particularly when we are performing cervicothoracic reconstruction and

internal fixation and fusion via the dorsal approach. The size of the cervical pedicles and, most importantly, their angle with respect to the lateral masses and the anteroposterior axis of the vertebral body are important. Knowledge of surgical anatomy is one of the greatest assets a surgeon can possess. This article contributes to that body of knowledge.

Mark N. Hadley
Birmingham, Alabama

Future Meetings—Congress of Neurological Surgeons

The following are the planned sites and dates for future annual meetings of the Congress of Neurological Surgeons:

2001	San Diego, CA	September 29–October 4
2002	Philadelphia, PA	September 21–26
2003	Denver, CO	October 18–23

Future Meetings—American Association of Neurological Surgeons

The following are the planned sites and dates for future annual meetings of the American Association of Neurological Surgeons:

2001	Toronto, Ontario, Canada	April 21–26
2002	Chicago, IL	April 6–11
2003	San Diego, CA	April 26–May 1